Lecture 5 Anatomy د.احمد فاضل

Anatomy of the mouth

The Lips

The lips are two fleshy folds that surround the oral orifice. They are covered on the outside by skin and are lined on the inside by mucous membrane. The substance of the lips is made up by the orbicularis oris muscle and the muscles that radiate from the lips into the face.

Also included are the labial blood vessels and nerves, connective tissue, and many small salivary glands. The philtrum is the shallow vertical groove seen in the midline on the outer surface of the upper lip.

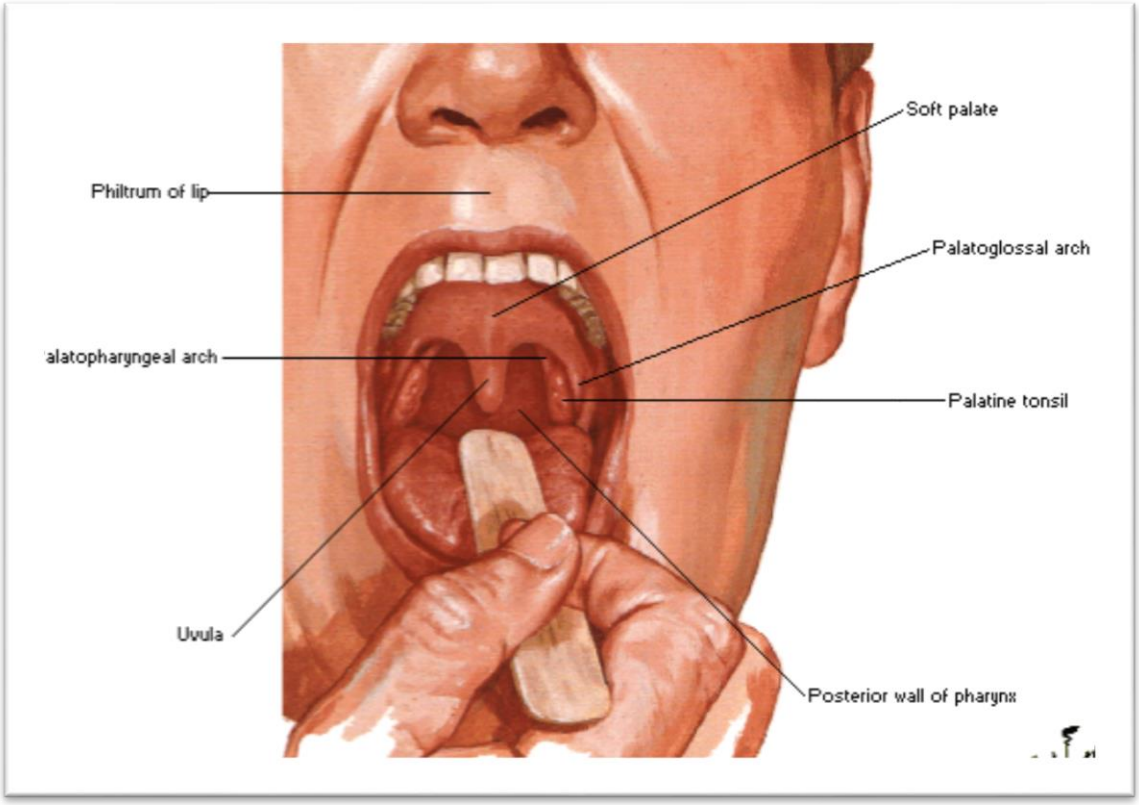

The oral Cavity

The mouth extends from the lips to the pharynx. The mouth is divided into the vestibule and the mouth cavity proper.

-Vestibule

The vestibule lies between the lips and the cheeks externally and the gums and the teeth internally. This slitlike space communicates with the exterior through the oral fissure between the lips. When the jaws are closed, it communicates with the mouth proper behind the third molar tooth on each side.

The duct of the parotid salivary gland opens on a small papilla into the vestibule opposite the upper second molar tooth.

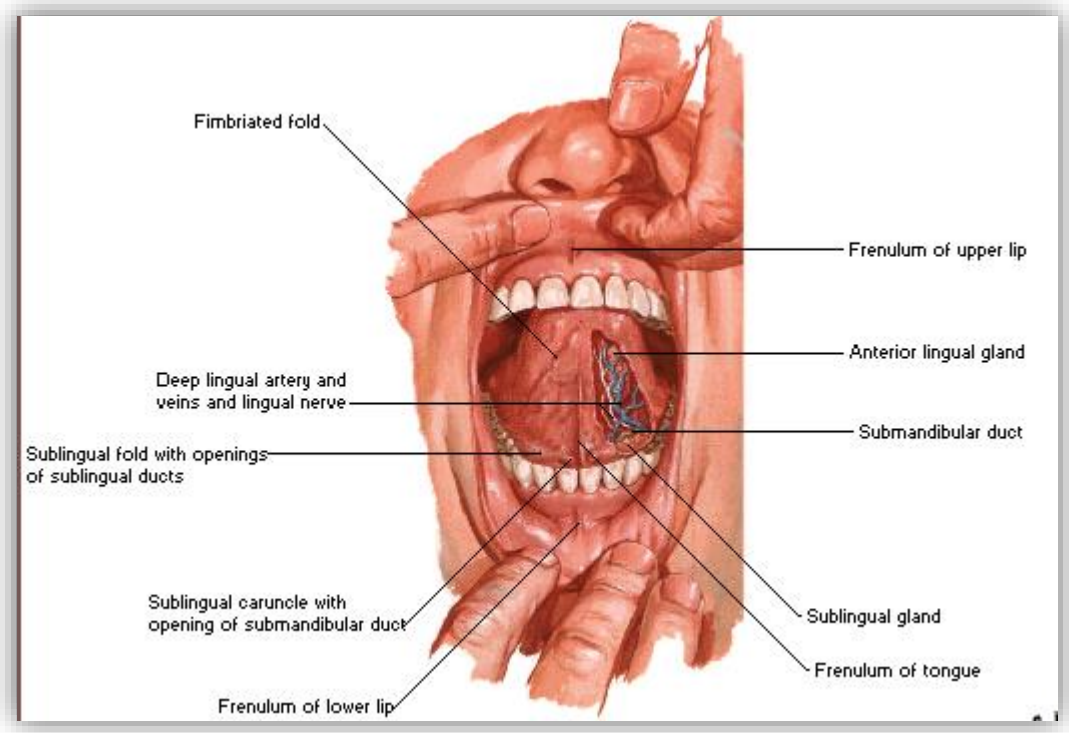

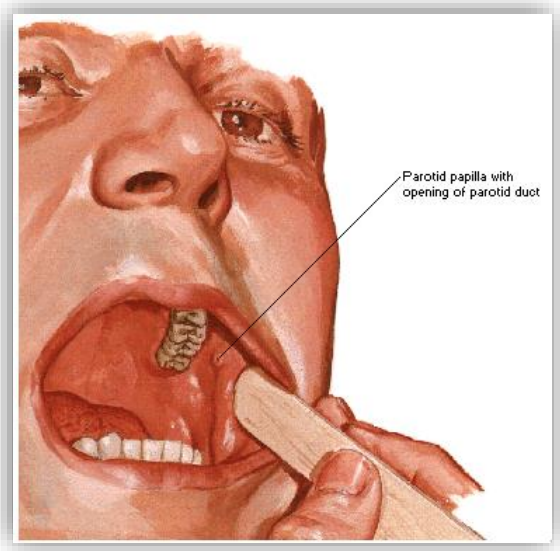

-Mouth Proper

The mouth proper has a roof and a floor.

Roof of Mouth

The roof of the mouth is formed by the hard palate in front and the soft palate behind.

Floor of Mouth

The submandibular duct of the submandibular gland opens onto the floor of the mouth on the summit of a small papilla on either side of the frenulum of the tongue. The sublingual gland projects up into the mouth, producing a low fold of mucous membrane, the sublingual fold (plica semilunaris) . Numerous ducts of the gland open on the summit of the fold.

Mucous Membrane of the Mouth

In the vestibule, the mucous membrane is tethered to the buccinator muscle by elastic fibers in the submucosa that prevent redundant folds of mucous membrane from being bitten between the teeth when the jaws are closed.

The mucous membrane of the gingiva, or gum, is strongly attached to the alveolar periosteum.

Sensory innervation of the Mouth

Roof: The greater palatine and nasopalatine nerves from the maxillary division of the trigeminal nerve

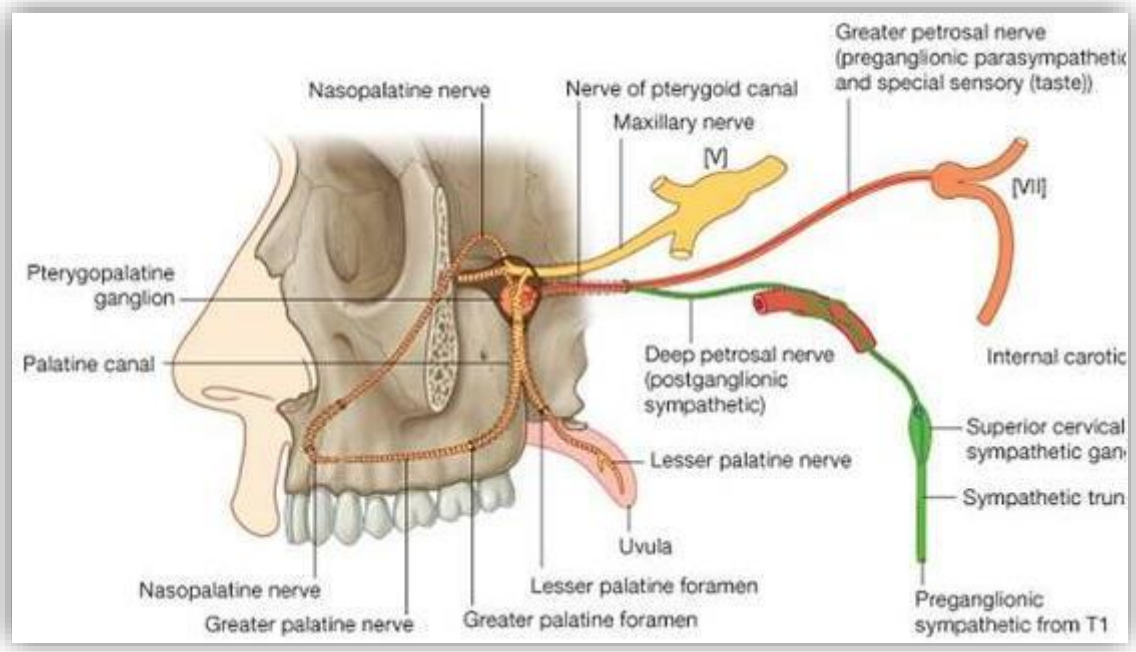

Hard Palate

The hard palate is formed by the palatine processes of the maxillae and the horizontal plates of the palatine bones

. It is continuous behind with the soft palate.

Soft Palate

The soft palate is a mobile fold attached to the posterior border of the hard palate. Its free posterior border presents in the midline a conical projection called the uvula. The soft palate is continuous at the sides with the lateral wall of the pharynx. The soft palate is composed of mucous membrane, palatine aponeurosis, and muscles.

Mucous Membrane

The mucous membrane covers the upper and lower surfaces of the soft palate.

Palatine Aponeurosis

The palatine aponeurosis is a fibrous sheet attached to the posterior border of the hard palate. It is the expanded tendon of the tensor veli palatini muscle.

Muscles of the Soft Palate
The muscles of the soft palate are the tensor veli palatini, the levator veli palatini, the palatoglossus, the palatopharyngeus, and the musculus uvulae.

The muscle fibers of the tensor veli palatini converge as they descend from their origin to form a narrow tendon, which turns medially around the pterygoid hamulus. The tendon, together with the tendon of the opposite side, expands to form the palatine aponeurosis. When the muscles of the two sides contract, the soft palate is tightened so that the soft palate may be moved upward or downward as a tense sheet.

Nerve Supply of the Palate
The greater and lesser palatine nerves from the maxillary division of the trigeminal nerve enter the palate through the greater and lesser palatine foramina .The nasopalatine nerve, also a branch of the maxillary nerve, enters the front of the hard palate through the incisive foramen. The glossopharyngeal nerve also supplies the soft palate.

Blood Supply of the Palate
The greater palatine branch of the maxillary artery, the ascending palatine branch of the facial artery, and the ascending pharyngeal artery
Lymph Drainage of the Palate
Deep Cervical Lymph Nodes

Palatoglossal Arch: The palatoglossal arch is a fold of mucous membrane containing the palatoglossus muscle, which extends from the soft palate to the side of the tongue. The palatoglossal arch marks where the mouth becomes the pharynx.

Palatopharyngeal Arch: The palatopharyngeal arch is a fold of mucous membrane behind the palatoglossal arch that runs downward and laterally to join the pharyngeal wall. The muscle contained within the fold is the palatopharyngeus muscle. The palatine tonsils, which are masses of lymphoid tissue, are located between the palatoglossal and palatopharyngeal arches.

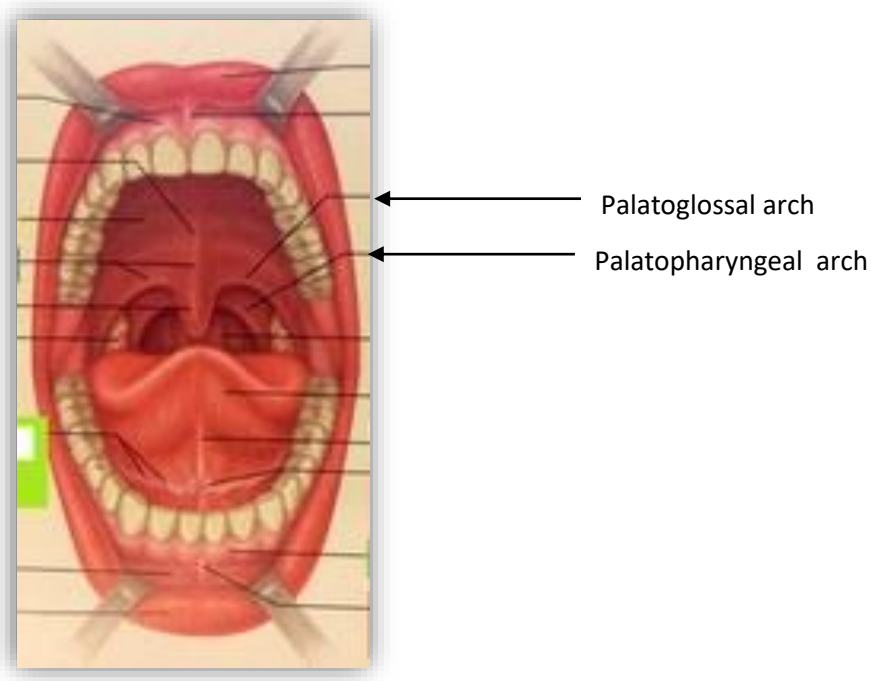

Movements of the Soft Palate

The pharyngeal isthmus (the communicating channel between the nasal and oral parts of the pharynx) is closed by raising the soft palate. Closure occurs during the production of explosive consonants in speech. The soft palate is raised by the contraction of the levator veli palatini on each side. At the same time, the upper fibers of the superior constrictor muscle contract and pull the posterior pharyngeal wall forward. The palatopharyngeus muscles on both sides also contract so that the palatopharyngeal arches are pulled medially, like side curtains. By this means, the nasal part of the pharynx is closed off from the oral part.

Muscle	Origin	Insertion	Nerve Supply	Action
Tensor veli palatini	Spine of sphenoid, auditory tube	With muscle of other side, forms palatine aponeurosis	Nerve to medial pterygoid from mandibular nerve	Tenses soft palate
Levator veli palatini	Petrous part of temporal bone, auditory tube	Palatine aponeurosis	Pharyngeal plexus	Raises soft palate
Palatoglossus	Palatine aponeurosis	Side of tongue	Pharyngeal plexus	Pulls root of tongue upward and backward, narrows oropharyngeal isthmus
Palatopharyngeus	Palatine aponeurosis	Posterior border of thyroid cartilage	Pharyngeal plexus	Elevates wall of pharynx, pulls palatopharyngeal folds medially
Musculus uvulae	Posterior border of hard palate	Mucous membrane of uvula	Pharyngeal plexus	Elevates uvula